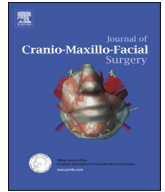



Contents lists available at ScienceDirect

## Journal of Cranio-Maxillo-Facial Surgery

journal homepage: www.jcmfs.com



## Redraping of the fat and eye lift for the correction of the tear trough

Ioannis E. Liapakis<sup>a,\*</sup>, Eleftherios I. Paschalis<sup>b</sup>, George J. Zambacos<sup>c</sup>, Miriam Englander<sup>b</sup>, Apostolos D. Mandrekas<sup>c</sup><sup>a</sup> *OpisClinical Plastic and Reconstructive Surgery, 48 Anogion St., 71304, Therissos, Heraklion-Crete, Greece*<sup>b</sup> *Massachusetts Eye and Ear Infirmary – Harvard Medical School, 243 Charles St., 02114, Boston, MA, USA*<sup>c</sup> *Artion Plastic Surgery Center, 11 D. Vassiliou St., N. Psyhiko, Athens, 15451, Greece*

## ARTICLE INFO

## Article history:

Paper received 3 December 2013

Accepted 22 April 2014

Available online xxx

## Keywords:

Redraping  
Blepharoplasty  
Mid-face lift  
Tear trough

## ABSTRACT

**Introduction:** Tear trough deformity is very difficult to correct. It can appear at relatively young age and it deepens over the years due to laxity and loss of structural support.

We describe a technique for the correction of tear trough deformity and mid-face laxity by means of redraping blepharoplasty and lateral “eye lift”.

**Materials and methods:** Upper lid markings were made and removal of the excess skin was employed. The herniated fat was removed from the nasal fat pad.

Using a subciliary incision the dissection was completed at the level of the orbital rim and the fat was repositioned with 5-0 *Monocryl (poliglecaprone 25, Ethicon)* sutures at the inner canthus to correct the tear trough. Subsequently, a canthopexy performed to secure the lower eyelid. We then dissected the cheek over the periosteum of the zygomatic bone-arch and the flap was suspended through a tunnel at the periosteum of the upper-lateral orbit by 5-0 *Monocryl (poliglecaprone 25, Ethicon)* suture.

**Results:** Thirty-five procedures were performed between 2009 and 2013. Patients were followed for at least one year. Successful correction of the tear trough deformity with middle face elevation was achieved in all patients. Sclera show was noted in 7 patients but resolved over 3–6 months period with no surgical intervention. Diplopia was noted in 1 patient probably due to oedema and was released 4 weeks after the operation. The oedema was prolonged (more than 1.5 month) in 10 patients probably due to the lymphatic stasis. Conjunctivitis was also noted in 2 patients and was released by conservative treatment.

**Conclusion:** Our technique of redraping blepharoplasty and mid-face lift describes a relatively new approach for the correction of the tear trough deformity and middle face laxity. It shows stable results for up to 4 years although longer follow-up is needed to confirm the stability of the correction.

© 2014 European Association for Cranio-Maxillo-Facial Surgery. Published by Elsevier Ltd. All rights reserved.

## 1. Introduction

The lower eyelids can become “tired” over the years and can be corrected by invasive or non-invasive procedures. “The tear trough” is the medial depression of the lower eyelid which worsens after the age of 30 and is very difficult to correct. Makeups, injection of hyaluronic acid or fat are temporary measures. Filler procedures will need to be repeated every six to nine months and the patient will be exposed to the risks and complications associated with filler procedures every time the procedure is performed. More permanent solutions include lipo-filling and mid-face lift (Mendelson,

1995; Yousif and Mendelson, 1995; Grabb and Smith's Plastic Surgery 5th Edition, 1997).

In this study we introduce an alternative approach for the correction of the tear trough and the sagging of the middle face. The technique involves redraping of the lower eyelid fat and suspension of the middle face to the lateral orbit of the upper eyelid.

## 1.1. Midfacial anatomy

The orbital septum is the anterior boundary of the orbit and its contents. It is a fibroelastic membrane and attaches to the lower orbital rim through the “arcus marginalis”.

The tear trough is the sharp definition between the cheek and lower lid and contains fat (prezygomatic fat as described by Mendelson, 1995).

\* Corresponding author. Tel.: +30 6932934051.

E-mail address: liapjo@yahoo.com (I.E. Liapakis).

Herniation of this fat with ageing can make tear trough more pronounced (Yousif and Mendelson, 1995), enhancing the dark cycles around the eyes.

The malar fat pad is a triangular subcutaneous structure based at the nasolabial fold with its apex at the malar eminence. It lies superficially to the Superficial Muscular Aponeurotic System (SMAS) (Yousif and Mendelson, 1995; Grabb and Smith's Plastic Surgery 5th Edition, 1997; Stuzin et al., 1992). Age related atrophy of this subcutaneous fat pad, results in the loss of the youthful, smooth transition between the lid and the lateral cheek.

The orbicularis oculi muscle may become flaccid and redundant which contributes to the formation of festoons. The anterior displacement of the orbital fat contributes finally to the lower eyelid bags (Hester et al., 2001).

## 2. Material and methods

Thirty-five patients were operated by the same Surgeon between 2009 and 2013 (at OpsisClinical, Plastic and Reconstructive Surgery, Heraklion-Crete, Greece). This was a prospective non-randomized clinical study, informed consent was obtained from all patients, none of them had prior blepharoplasty and they were aged from 33 to 68 years old. All the patients were asked to complete a questionnaire (from one to five) in order to note their satisfaction (Table 1). Student's *t*-test ( $p < 0.05$ ), was used to analyse the results.

### 2.1. Preoperative evaluation

The upper lid was evaluated for extra skin and orbital fat herniation.

**Table 1**

Patients' characteristics and complications undergoing redraping of the fat and eyelift for the correction of the tear trough.

Patient	Gender	Age	Follow-up (months)	Type of the lesion (1–5)*	Complications
1	Female	67	3	4	Sclera show
2	Female	50	12	3	Conjunctivitis
3	Female	53	6	3	Prolonged edema
4	Female	44	24	2	Sclera show
5	Female	44	36	2	None
6	Female	33	8	1	Prolonged edema
7	Female	51	4	2	None
8	Female	34	3	1	Sclera show
9	Female	39	12	1	Sclera show
10	Female	53	6	4	None
11	Female	49	9	5	Prolonged edema
12	Female	54	7	4	None
13	Female	58	12	3	None
14	Female	47	5	2	Prolonged edema
15	Female	44	6	3	None
16	Female	46	7	4	None
17	Female	49	8	2	Sclera show
18	Female	56	3	3	Prolonged edema
19	Female	50	12	4	None
20	Female	49	36	2	None
21	Female	51	60	3	Prolonged edema
22	Female	48	5	5	None
23	Female	46	8	4	Conjunctivitis
24	Male	53	4	3	Prolonged edema
25	Female	62	6	5	None
26	Female	49	9	4	Sclera show
27	Female	54	5	3	Prolonged edema
28	Female	57	12	4	None
29	Female	63	3	4	None
30	Female	67	24	5	Prolonged edema
31	Female	49	6	4	None
32	Female	45	7	3	Prolonged edema
33	Female	42	48	3	None
34	Female	59	8	4	Sclera show
35	Female	68	12	5	Diplopia

\* Type of the lesion: 1 for tear trough, 5 for tear trough with festoons.

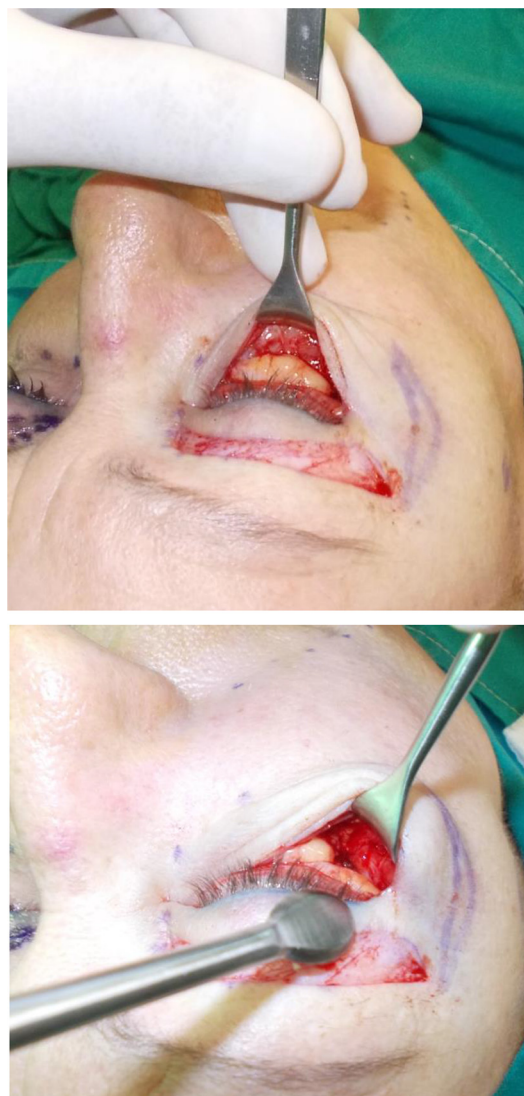Lower lid was examined by snap test; sclera show was noted as well as the presence of herniated orbital fat (Furnas, 1978). Tear trough deformity, malar bags or festoons, lateral cheek laxity was also evaluated (Jelks and Jelks, 1993).

### 2.2. Surgical technique

The skin was sterilized in the usual fashion. Upper lid markings were made and the topical anaesthesia was introduced as already described elsewhere (Hester et al., 2001). Dissection and removal of the excess skin was employed by scalpel at the upper eyelid and the herniated fat was carefully removed from the nasal fat pad via the septum.

Subsequently, the lower lid skin incision was started 1 cm temporal to the lateral canthus. The tissue was dissected to the periosteum of the lateral orbital rim and the incision was then extended along the lower lid margin while preserving a small strip of pretarsal orbicularis muscle.

Blunt dissection to the periosteum of the infraorbital rim was performed to release the arcus marginalis and the dissection was extended laterally above the zygomatic bone–arch (Fig. 1). Special



**Fig. 1.** Photos from the lower eyelid: upper) notice the lower eyelid fat pads before redraping and the inner canthus, lower) notice the rim of the concha before releasing it from the soft tissues with the dissector.

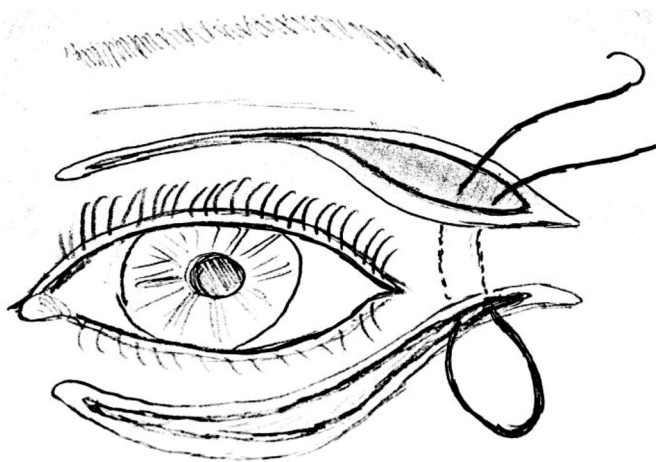


Fig. 2. Canthopexy is performed to tighten the lateral canthus to the upper orbital rim.

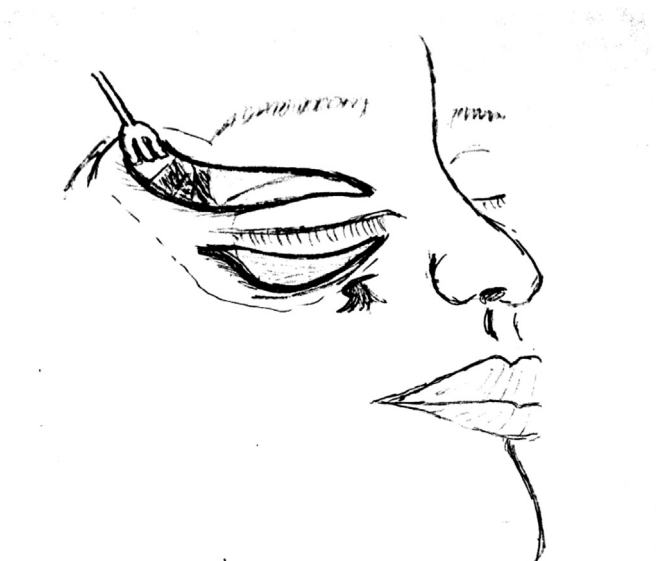


Fig. 3. The orbicularis muscle and the soft tissue from the mid-face are suspended to the periosteum of the upper-lateral orbital rim.

care was given to avoid injury of the infraorbital nerve. The tear trough deformity was then corrected by repositioning the medial fat pad nasally to the bone with interrupted 5-0 *Monocryl* (*poliglecaprone 25, Ethicon*) sutures. Excess fat was excised with caution from the lower lid fat pads to optimize the aesthetic result. A 5-0 *Monocryl* (*poliglecaprone 25, Ethicon*) anchoring suture was then performed (through the upper eyelid incision) to the periosteum of the upper-lateral orbit. The suture was used to secure the lower eyelid through a tarso-ligamentous sling as a canthopexy (Fig. 2).

The suture was not cut, but was passed through a subcutaneous tunnel in order to elevate the malar fat pad to the upper-lateral orbit (Fig. 3).

Excess lower lid skin was excised conservatively (Jelks and Jelks, 1993).

### 3. Results

The tear trough deformity and mid-face laxity was dramatically improved in all patients. The complications seen were not significantly higher than those for standard transcutaneous blepharoplasty techniques (Grab and Smith's Plastic Surgery, 5th Edition 1997; Stuzin et al., 1992; Hester et al., 2001), except from the oedema which was released in all the cases. Diplopia was noted in 1 patient probably due to oedema and was released 4 weeks after the operation. Scleral show was noted in 7 patients but resolved over 3–6 months period with no surgical intervention. Conjunctivitis was also noted in 2 patients and was released after 1 month by conservative treatment. The oedema was prolonged (more than 1.5 month) in 10 patients (Table 1) probably due to the lymphatic stasis. Smoking and an age over 45 seemed to be critical factors although the oedema was diminished with ice and gentle massage.

Thirty two patients were very satisfied with the results, 2 were almost satisfied because “there was a small improvement” in their lower eyelid and one was dissatisfied because “there was no improvement” at her tear trough.

### 4. Discussion

In blepharoplasty patients, orbital fat excision or fixation has been used to optimize the result. Furnas (1978), was the first to describe the resection of the orbicularis muscle and suspension of the lower eyelid to the lateral orbital rim. An alternative approach of excision of the herniated fat and plaction of the orbital septa described by Huang (2000). Adamson et al., (1991) extended the

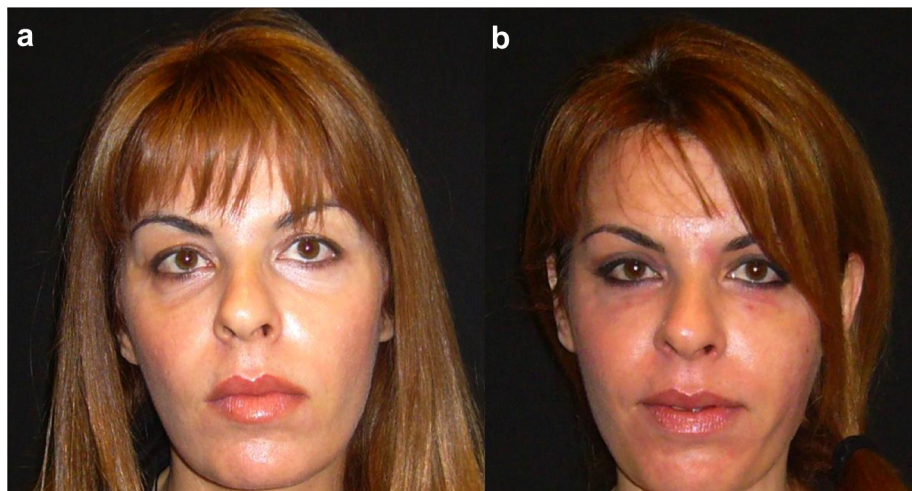

Fig. 4. Patient with tear trough deformity and sagging of the middle face. Photos left) before and right) 1 year post operatively.



dissection of the skin-muscle flap below the infraorbital rim. Hamra (1992) and Hamra (1998), was the first to propose the release of the arcus marginalis for patients with prominent nasojuveal or malar fold. A combination of face lift and

blepharoplasty was proposed by Hinderer et al. (1987). Hester et al. (2001) and Hester et al. (2000) were the first to correct malar bags through subciliary incision and suspension of the orbicularis muscle.

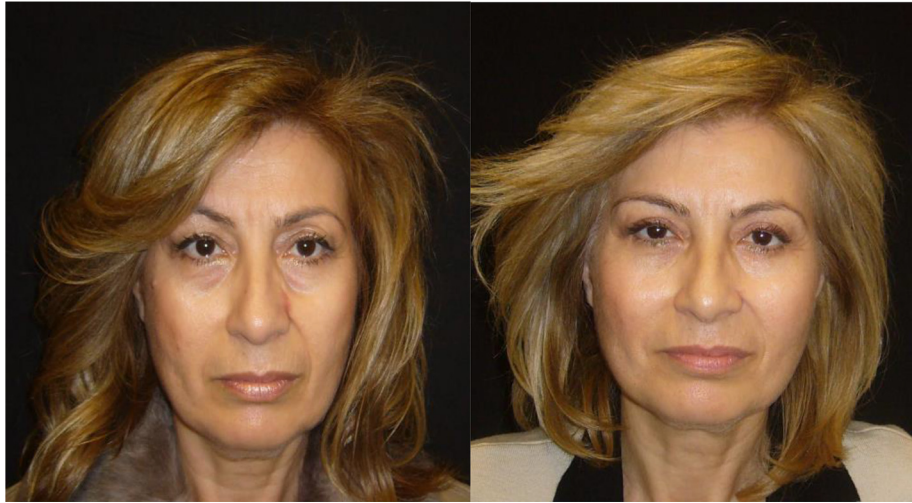

Fig. 5. Patient with tear trough deformity. Photos left) before and right) 1 year post operatively.



Fig. 6. Patient with tear trough deformity and sagging of the middle face. Photos left) before, right) 1.5 months after redraping blepharoplasty, middle face lift and direct eyebrow lift. Notice the sclera show in both lower eyelids, below) 6 months after the operation. The sclera show released with no surgical intervention.

Tessier (1989) and Psillakis et al. (1988) described a subperiosteal face lift through a coronal or a superior orbital rim incision. Unfortunately, both of these techniques were complicated by high rate of facial frontal nerve palsy (Psillakis et al., 1988). Ramirez et al. (1991) and Ramirez (1992) were the first to describe endoscopic upper and middle face lift. The technique, however, had not become popular due to the steep learning curve and the high cost of the required equipment. Le Luarn C (2004), also proposed an entire middle face lift by placing 3 sutures: one to elevate the malar fat pad, one to increase the malar volume and one to suspend the orbicularis muscle. A mid-face lift can be performed either by coronal or subciliary incision.

The disadvantages of the coronal incision include changes in the orientation of the external canthus and facial palsy (Liapakis and Pachalis, 2012). The subciliary incision allows better anatomical visualization and helps the suspension of the soft tissue to the orbital rim. In addition, when performed with canthopexy or canthoplasty it decreases the risk of ectropion

(Fagien, 1999; Gunter and Hackney, 1999; Hobar and Flood, 1999).

Our technique is very simple and effective (Figs. 4–8). We perform a canthopexy and a horizontal tightening because if we don't correct the lower lid laxity, the patient might develop an ectropion or retraction of the lid. The typical blepharoplasty procedure address to the remove of the excess fat and skin from the lower eyelid. However, it will not correct the tear trough without redraping of the orbital fat and lateral eye lift.

It is very critical to dissect close to orbital bone medially and the maxilla laterally in order to maximize the result. The lower eyelid is then secured by canthopexy and the cheek is elevated by suturing the orbicularis muscle to the lateral orbital rim periosteum by a 5-0 Monocryl (poliglecaprone 25, Ethicon) suture.

Some patients have malar festoons which can be corrected with our technique. Others do not have bags under their eyes, but instead they have excessive hollowing at the orbital rim. Our technique would be ideal for such cases and can achieve dramatic



**Fig. 7.** Patient with tear trough deformity and sagging of the middle face. Photos (left) before, (right) 3 weeks post operatively. Notice the oedema especially under the area of the dissection, (below) 1 year post operatively. Notice the oedema released.

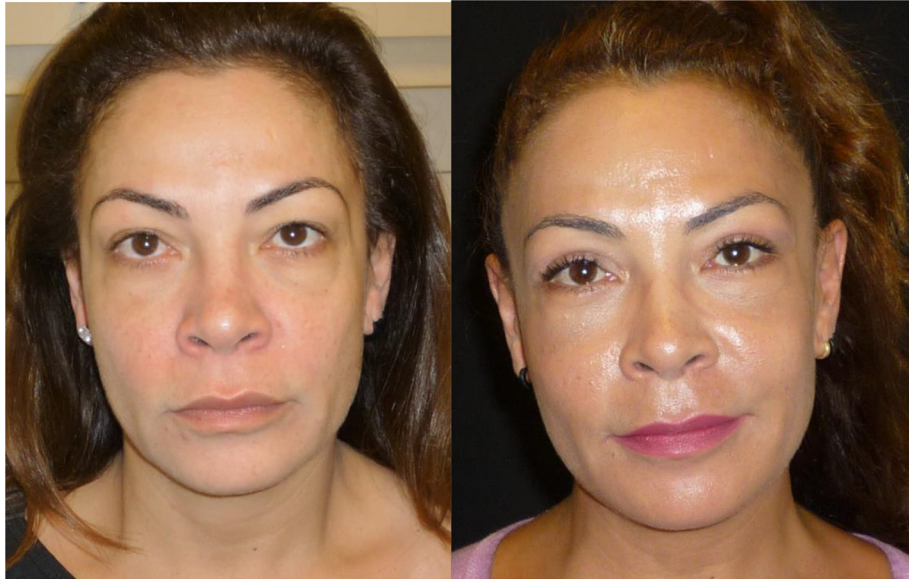

Fig. 8. Patient with tear trough deformity. Photos left) before and right) 3 months post operatively.

results. It is minimally invasive compared to the middle face lift (Le Louarn, 2004; Liapakis and Pachalis, 2012), since it does not require drilling of the inferior orbital rim. It can be combined with direct eyebrow lift for optimal result when needed (Fig. 6). The scar is inconspicuous and the complication rates are the usual blepharoplasty ones.

## 5. Conclusion

In this study we describe an effective technique for the correction of both, tear trough deformity and mid-face laxity. The fat redraping and lateral “eye lift” have stable results with some follow-up extending out to four years. Longevity of results is similar or better than those expected with standard blepharoplasties, as the modified technique creates lifting of the tissues.

## Acknowledgement

The authors have nothing to disclose.

## References

- Adamson PA, Tropper GJ, McGraw BL: Extended blepharoplasty. *Arch Otolaryngol Head Neck Surg* 117(6): 606–610, 1991 Jun
- Fagien S: Algorithm for canthoplasty: the lateral reticular suspension: a simplified suture canthopexy. *Plast Reconstr Surg* 103(7): 2042–2053, 1999 Jun, discussion 2054–2058
- Furnas DW: Festoon of orbicularis muscle as a cause of baggy eyelids. *Plast Reconstr Surg* 61(4): 540–546, 1978 Apr
- Gunter JP, Hackney FL: A simplified transblepharoplasty subperiosteal cheek lift. *Plast Reconstr Surg* 103(7): 2029–2041, 1999 Jun
- Grabb and Smith's Plastic Surgery. In: Aston SJ, Beasley RW, Thorne CH (eds), 5th ed. Philadelphia, New York: Lipincott-Raven, 609–633, 1997
- Hamra ST: Repositioning the orbicularis oculi muscle in the composite rhytidectomy. *Plast Reconstr Surg* 90(1): 14–22, 1992 Jul
- Hamra ST: The zygorbicular dissection in composite rhytidectomy: an ideal midface plane. *Plast Reconstr Surg* 102(5): 1646–1657, 1998 Oct
- Hester Jr TR, McCord CD, Nahai F, Sassoon EM, Codner MA: Expanded applications for transconjunctival lower lid blepharoplasty. *Plast Reconstr Surg* 108(1): 271–272, 2001 Jul
- Hester TR, Codner MA, Mc Cord CD, Giannopoulos A: Evolution of technique of the direct transblepharoplasty approach for the correction of lower lid and mid-facial aging: maximizing results and minimizing complications in a 5-year experience. *Plast Reconstr Surg* 105(1): 393–406, 2000 Jan, discussion 407–408
- Hinderer UT, Uriolagoita F, Vildosola R: The blepharo-periorbitoplasty: anatomical basis. *Ann Plast Surg* 18(5): 437–453, 1987 May
- Hobar PC, Flood J: Subperiosteal rejuvenation of the midface and periorbital area: a simplified approach. *Plast Reconstr Surg* 104(3): 842–853, 1999 Sep
- Huang T: Reduction of lower palpebral bulge by placating attenuated orbital septa: a technical modification in cosmetic blepharoplasty. *Plast Reconstr Surg* 105(7): 2552–2600, 2000 Jun
- Jelks GW, Jelks EB: Preoperative evaluation of the blepharoplasty patient: bypassing the pitfalls. *Clin Plast Surg* 20(2): 213–224, 1993 Apr
- Le Louarn C: The concentric malar lift: malar and lower eyelid rejuvenation. *Aesthetic Plast Surg* 28(6): 359–374, 2004 Nov–Dec
- Liapakis IE, Pachalis EI: Liposuction and suspension of the orbicularis oculi for the correction of persistent malar bags: description of technique and report of a case. *Aesthetic Plast Surg* 36(3): 546–549, 2012
- Mendelson BC: Extended sub-SMAS dissection and cheek elevation. *Clin Plast Surg* 22(2): 325–339, 1995 Apr
- Psillakis JM, Rumley TO, Camargos A: Subperiosteal approach as an improved concept for correction of the aging face. *Plast Reconstr Surg* 82(3): 383–394, 1988 Sep
- Ramirez OM, Maillard G, Musole A: The extended subperiosteal face lift: a definitive soft-tissue remodeling for facial rejuvenation. *Plast Reconstr Surg* 88(2): 227–238, 1991 Aug
- Ramirez OM: The subperiosteal rhytidectomy: the third generation face-lift. *Ann Plast Surg* 28: 218–234, 1992
- Stuzin JM, Baker TJ, Gordon HL: The relationship of the superficial and deep facial fascia: relevance to rhytidectomy and aging. *Plast Reconstr Surg* 89(3): 441–451, 1992 Mar
- Tessier P: The subperiosteal face lift. *Ann Chir Plast Esthet* 34(3): 193–197, 1989
- Yousif NJ, Mendelson BC: Anatomy of the midface. *Clin Plast Surg* 22(2): 227–240, 1995 Apr